

ENROLLING CENTER CARDIAC MRI PROCESSING AND TRANSFER

OVERVIEW

Cardiac MRI (CMRI) test is required for all subjects enrolled in the ARVC study if performed per standard of care. If CMRI is done for diagnosis purposes at the enrolling center after consent form is signed (not previously done by outside source), they should be done using the standardized ARVC protocol in this manual. If CMRI was performed prior to enrollment, a copy of the latest test CD/DVD and/or the test that was done for ARVC diagnosis purposes should be sent along with the written report and completed Form 4J and Form 4A. Any new CMRI done prior to a specific follow –up visit must be sent to the CMRI core lab as soon as it is done and the required CRFs should be completed in the subsequent yearly visit event in the ARVC electronic data entry system.

CMRI AT BASELINE

1. Transferring the CMRI CD/DVD and Reports for a **New** Potential Proband: The CMRI written report must be sent to the Clinical Center Reviewer for ARVC diagnosis. Once the ARVC diagnosis is verified by the Clinical Center Reviewer, the CMRI CD/DVD must be transferred to the CMRI core lab. It is possible that the Clinical Center Reviewer will request the CMRI images apart from the written reports to assess patient's eligibility, in this case, the CMRI CD/DVD must be sent or transferred within 5 working days from date of request to the Clinical Center Reviewer.
2. Transferring the CMRI CD/DVD and Reports for Family member (old/new) and **Old** Probands: Once the proband in the family is identified, or a subject from the previous grant is enrolled (proband/family member), the CMRI CD/DVD and written report must be sent to the CMRI Core lab. Forms 4J and 4A must be completed and sent together with the Media.

CMRI AT FOLLOW-UP VISITS

If CMRI is performed while a subject (old/new proband or old/new family member) is participating in the study, we recommend that the standardized protocol in this manual should be used. The CD/DVD and written report should be sent at the next sequential follow-up study visit following the procedure. Each sent media must be accompanied by a completed Form 4J and a completed Form 4A.

TEST MEDIA TRANSFER

First delivery of the data must be attempted by uploading the data electronically, according to instructions in the Data Transfer section of this manual. If data upload is unsuccessful, send the data to the MRI Core lab using Fed Ex.

MANUAL TRANSFER

Contact Information

If further information is needed about the CMRI protocol, contact Dr. Liu at the NIH Clinical Center as noted below.

If manual transfer is required, then the electronic media should be sent to:

CHIA LIU, PHD
Staff Scientist, Radiology and Imaging Sciences
National Institutes of Health Clinical Center
10 Center Drive, Room 1C612
Bethesda, Maryland 20892 USA
Phone: 301-402-5729
Fax: 301-480-1116
Email: chia-ying.liu@nih.gov

Core Laboratory Director Contact Information if needed:

DAVID BLUEMKE, MD, PhD
Director, Radiology and Imaging Sciences
National Institutes of Health Clinical Center
10 Center Drive, Room 1C355
Bethesda, Maryland 20892 USA
Phone: 301-402-1854
Fax: 301-480-0055
Email: bluemked@nih.gov

Delivery of the report to the **Clinical Review Center** for new proband ARVC evaluation must be attempted by uploading the data electronically, according to instructions in the test transfer section. If data upload is unsuccessful, send the data via mail or fax as instructed in the test transfer section.

Table 1: Test Media Transfer

	Test Media Transferred Baseline Visit		Test Media Transferred Follow-Up Visit
	Subject Category		
	➤ New Proband	➤ Old Proband ➤ New Family Member ➤ Old Family member	➤ Old Proband ➤ New Proband ➤ New Family Member ➤ Old Family member
	Transfer to Clinical Center Reviewer	➤ Clinical Center Data Shipment Form (Form 5B) ➤ CMRI Form (Form 4J) ➤ Written report	
	Transfer to CMRI Core Laboratory	➤ Shipping Form (Form 4A) ➤ CMRI Form (Form 4J) ➤ CD/DVD ➤ Written report	➤ Shipping Form (Form 4A) ➤ CMRI Form (Form 4J) ➤ CD/DVD ➤ Written report



NATIONAL INSTITUTES OF HEALTH CLINICAL CENTER

Radiology and Imaging Sciences

**GENETICS, MECHANISMS AND CLINICAL
PHENOTYPES OF ARRHYTHMOGENIC
CARDIOMYOPATHY**

CMR Field Center Manual

ARRHYTHMOGENIC CARDIOMYOPATHY (AC) CMR Field Center Manual

Chia Liu, PHD
David A. Bluemke, MD PhD

2014-May-08

Version 1.2

Table of Contents

1.	Introduction	3
2.	Site Certification	3
3.	General Overview	4
4.	Abbreviations.....	6
5.	Sequence Naming Standard.....	7
6.	Patient Preparation.....	8
7.	CMR Protocol.....	9
1)	Check the MRI Completion Form.....	9
2)	Multi-Planar Scout.....	9
3)	Axial Cine images	9
4)	Axial Black Blood images	11
5)	Pseudo Vertical Long Axis Scout.....	12
6)	Pseudo Horizontal Long Axis Scout.....	12
7)	Short Axis Scout	13
8)	Cine Four-Chamber (horizontal long axis).....	14
9)	T1 mapping: Pre-Contrast: four chamber view.....	14
10)	Cine Right Chamber Two-Chamber (vertical long axis).....	15
11)	Gadolinium Injection – Magnevist only.	16
12)	Cine Short Axis	16
13)	Cine Two-Chamber (vertical long axis).....	18
14)	T1 mapping: Post-Contrast -- 4 chamber view	18
15)	TI Scout (Siemens), Look-locker (Philips). 4 chamber view... 	18
16)	Short Axis SSFP Delayed Enhancement.....	19
17)	Fast Gradient Echo Delayed Enhancement Short axis	20
18)	Fast Gradient Echo Delayed Enhancement Long axis.....	21
8.	CMR Protocol Installation.....	22
9.	Contact Information	22
10.	Update History	22

1. Introduction

The Radiology and Imaging Sciences department of National Institutes of Health Clinical Center will serve as the cardiac magnetic resonance (CMR) core laboratory for the GENETICS, MECHANISMS AND CLINICAL PHENOTYPES OF ARRHYTHMOGENIC CARDIOMYOPATHY study. The focus of the CMR examination is to provide accurate data on the morphology and function of the right ventricle. In addition, tissue composition of the myocardium will also be assessed.

2. Site Certification

Enrolling center certification is not required for the ARVC study.

3. General Overview

This protocol includes the following sections.

- 1) **Localizer:** Scout images to determine the position of the patient in the isocenter of the magnetic field.
- 2) **T1 weighted images:** Axial TSE/ FSE images with black blood technique is used to obtain information on the morphology of the RV and LV. 5-7 slices are obtained starting just above the diaphragm and extending superiorly to the aortic root. Slice thickness 5 mm, skip 5 mm.
- 3) **Axial Cine image:** Cine images acquired in the axial planes from the diaphragm to the aortic root. 8 mm thick, skip 2mm.
- 4) **Pre-contrast T1 map:** These images are used to measure T1 value of the myocardium. MOLLI (Modified Look Locker Inversion Recovery) is used. A horizontal long axis view is obtained.
- 5) **Gadolinium injection:** 0.15mmol/kg total dose of gadolinium based contrast agent (Magnevist strongly encouraged – please inform CMR center if this is NOT available) administered prior to short axis cine imaging.
- 6) **Cine image:** Cine images acquired in the short-axis planes from the base (atria) to the apex, using the SSFP sequence. Long-axis SSFP cine images are also acquired in the four-chamber, two-chamber. In addition, a long axis RV view is obtained, parallel to the septum.
- 7) **Post-contrast T1 mapping:** Acquired at 12 and 25 minutes after Gd injection in the EXACT same position and with the same parameters as the pre-contrast T1 mapping.
- 8) **TI time determination:** A Look-locker sequence will be performed to help select the optimal TI for viability imaging. A short axis, mid-ventricular slice is obtained.
- 9) **Single-shot delayed enhancement (if available):** Acquired in the same slice position as short axis cine; however, all slices will be acquired in one breath-hold with SSFP sequence.

- 10) **Fast gradient echo (multiple-shot) delayed enhancement:** Images acquired after the contrast agent injection, in the same short-axis and long-axis planes as the cine series. A segmented phase sensitive inversion recovery (PSIR) spoiled gradient recalled echo (GRE) sequence is used. The inversion time is optimized based on the Look-Locker sequence.
- 11) **Parallel imaging:** All 2D sequences (SSFP and GRE) will use parallel imaging with an acceleration factor of 2.
- 12) **Hematocrit:** For all subjects with post-contrast T1 mapping, hematocrit is necessary.

Sites are required to complete Form 9F for each patient. Steps for image acquisition and the MR sequence parameters for the protocol are given below. Vendor-specific implementations of the protocol are also provided.

Summary of “unique” features of the AC CMR protocol for the technologist:

1. Timing of the MOLLI delayed T1 sequence at 12, 25 minutes is critical. Please use/ acquire a timer or stopwatch for this purpose.
2. The EXACT dose of gadolinium is critical. Do not round up or round down gadolinium doses.
3. 50 phases are used for all cine sequences.

4. Abbreviations

AC:	Arrhythmogenic cardiomyopathy
BH:	Breath hold
CMR:	Cardiac magnetic resonance imaging
ECG:	Electrocardiography
GRE:	Gradient recalled echo
IR:	Inversion recovery
NBH:	Non breath hold
PSIR:	Phase sensitive inversion recovery
SSFP:	Steady state free precession
TSE:	Turbo spin echo (equivalent to fast spin echo)
VLA:	Ventricular long axis
HLA:	Horizontal long axis
MOLLI:	Modified Look Locker Inversion Recovery

5. Sequence Naming Standard

Please name the sequences on the scanner according to the left column, the right column is for your information.

Name	Definition
_3_PLANE_SCOUT	(three plane scout)
AX_T1_BB	(black blood T1-weighted images)
AX_CINE	(axial cine)
PVLA_SCOUT	(pseudo-vertical long axis scout)
PHLA_SCOUT	(pseudo-horizontal long axis scout)
SA_SCOUT	(short axis scout)
HLA_CINE	(horizontal long axis / four-chamber cine)
VLA_CINE	(vertical long axis / two-chamber cine)
VRA_CINE	(right ventricular vertical long axis / two-chamber cine)
SA_CINE	(short axis cine)
T1_MAP_PRE	(pre-contrast T1 map)
TI_SCOUT	(TI scout on Siemens, Look Locker on Philips)
SA_GRE_DE	(short axis gradient echo delayed enhancement)
HLA_GRE_DE	(horizontal long axis gradient echo delayed enhancement)
VLA_GRE_DE	(vertical long axis gradient echo delayed enhancement)
AX_GRE_DE	(axial gradient echo delayed enhancement)
T1_MAP_POST_12min	(post-contrast T1 map at 12 mins)
T1_MAP_POST_25min	(post-contrast T1 map at 25 mins)
SA_SSFP_DE	(short axis SSFP delayed enhancement)

6. Patient Preparation

- 1) Complete the MRI safety screening form of your MRI center. AC participants are not pre-screened for MRI safety / compatibility.
- 2) **Request that patient use the rest room before the CMR study.**
- 3) Breath-holding is done at resting lung volume for the entire AC protocol. The participant must be able to hold their breath for 15 seconds at resting lung volume twice in order to participate in the protocol. Inform and train the participant on breath-holding, for example: “Breathe in ... Let air out until you are comfortable, and then stop breathing.”
- 4) Make sure that the connectors for cardiac coils and ECG are in place.
- 5) Thoroughly clean the ECG contact area with alcohol wipe. With patient supine on the scanner table, attach ECG electrodes to his/her chest according to your MRI manufacturer suggestion.
- 6) Place a 20-22 ga. cannula in the **right** antecubital vein. If venous access is not available, gadolinium may be administered more cautiously, including by butterfly needle under direct observation. Note that lack of venous access is not a protocol contraindication to MRI scanning
- 7) Prepare a dose of gadolinium-based contrast agent (0.15mmol/kg) with 40ml saline flush.
- 8) For all the subjects with T1 mapping, hematocrit is necessary.

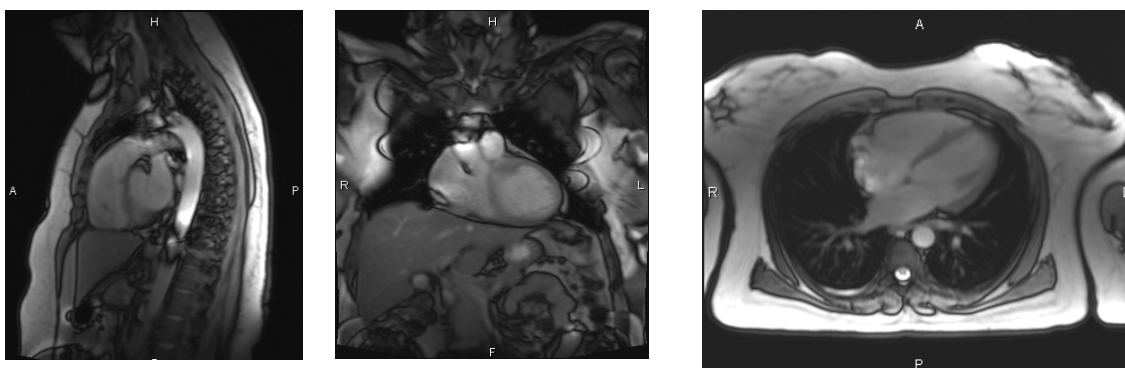
7. CMR Protocol

1) Check the MRI Completion Form

Please check the exclusion and eligibility form, complete the CMRI form (Form 9F) at the end of the scan. And the shipping form (Form 4A)

2) Multi-Planar Scout

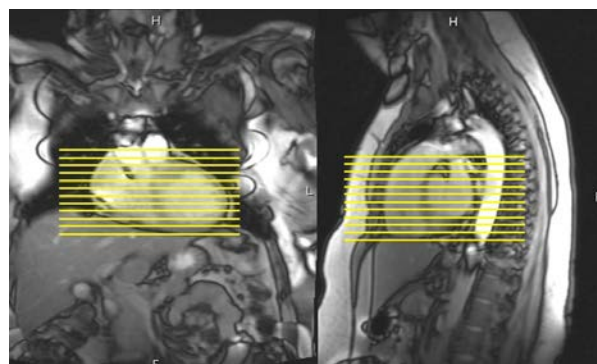
The first multi-plane localizer acquired with free breathing to move the heart to the isocenter of the magnet. The second breath hold localizer acquired with three slices in three orthogonal planes (axial, coronal and sagittal, 3 slices per view, 9 slices in total). Perform the BH localizer **at resting lung volume**.

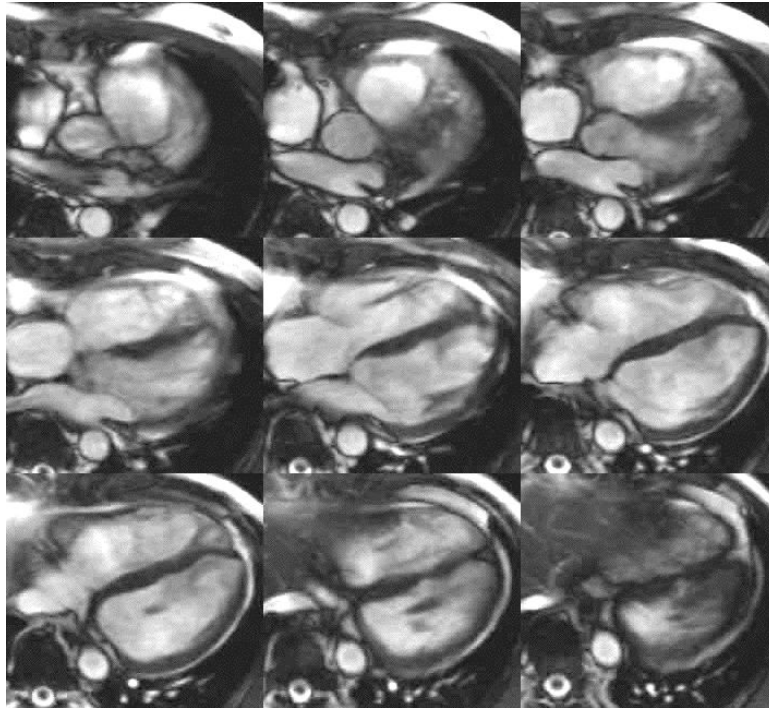


3) Axial Cine images

Approximately 7 axial cine images are obtained from the diaphragm to the aortic valve. The prescription for axial images is based on the Sagittal and coronal localizers as follows:

The resulting stack of cine axial images is displayed below (note the images are cropped over the heart. Your images will display a full field of view):

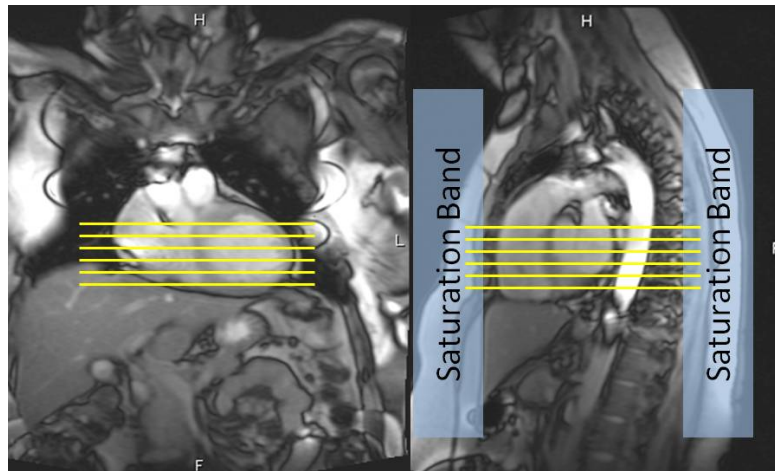




CINE Imaging	Recommended Protocol	Vendor Specific Protocol		
		Siemens	GE	Philips
Sequence	SSFP	True FISP	FIESTA	B-FFE
TR (ms)	minimize	Min	Min	Sh
TE (ms)	minimize	Min	Min Full	Sh
Flip Angle (degrees)	maximize	Max°	70°	65°
Field of View (mm)	Depending on patient size			
Spatial Resolution (mm)	Better than 2.5*2.0*8.0			
Image Matrix	At least 128*256			
Slice Thickness (mm)	8 mm	8	8	8
Slice Gap (mm)	2 mm	2	2	2
Number of slices	Minimum of 12 short axis 1 vertical long axis 1 horizontal long axis 1 three-chamber view	Same as recommended	Same as recommended	Same as recommended
Bandwidth (Hz/pixel)	≥ 900	≥ 900	125kHz, 977 Hz/pixel	961
Parallel Imaging	Acceleration factor: 2	GRAPPA	ASSET	SENSE
Partial Fourier	No	off	No	No
Gating	Retrospective	ECG/Retro	ECG/Retrospective	Retrospective
Number of segments	≤ 20	≤ 16	12	
Temporal Resolution (ms)	30-50 msec	≤ 50	≤ 50	≤ 50
Calculated Phase	50			
Breath-hold time (s)	≤ 15	≤ 15	≤ 15	≤ 15

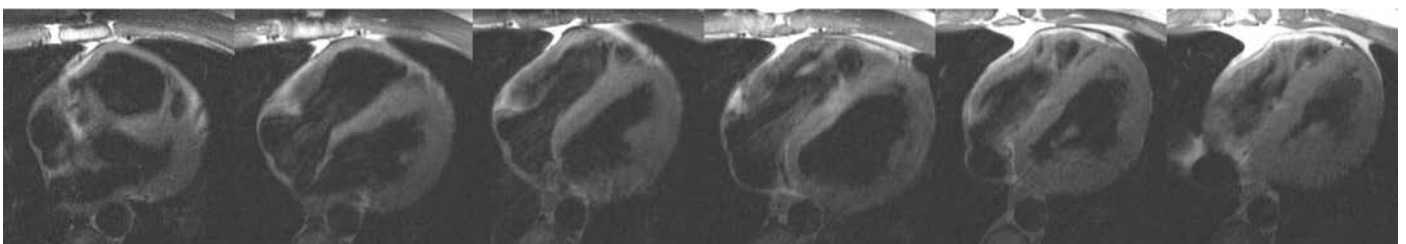
4) Axial Black Blood images

A stack of 7 black blood TSE/ FSE black blood images is obtained in an axial orientation. These are centered over the ventricles. Each slice is one breath-hold. The slice thickness is 5 mm, and the gap is 5 mm. The TE time is sent to minimum. These are multi-slice techniques: images should be prescribed from the diaphragmatic surface superiorly towards the outflow tract. ECG gated spin echo, transaxial plane, to cover from the lower ventricle to the upper ventricle. A saturation band over the anterior chest wall is required. The appropriate prescription and resulting images are shown below:



Resulting stack of axial black blood images. Note these images are cropped to show only the ventricle.

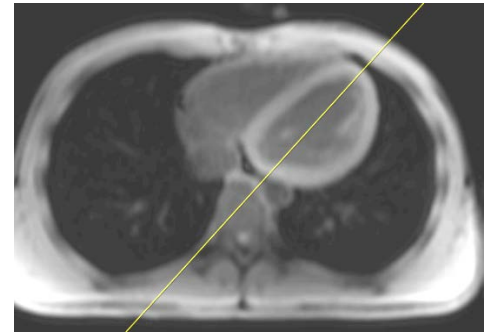
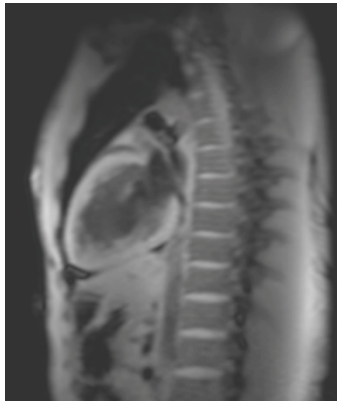
Your prescription will show the full field of view.



5) Pseudo Vertical Long Axis Scout

This is a dark blood, breath-hold, one slice (non-cine) image.

Prescribe this using the axial scout view with the largest volume of heart, from the base (middle of the mitral valve) to apex of the left ventricle. Perform the localizer **at resting lung volume**.

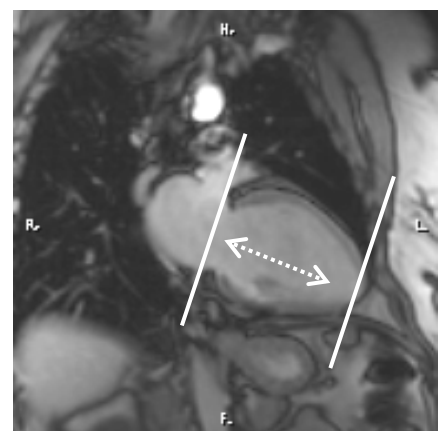
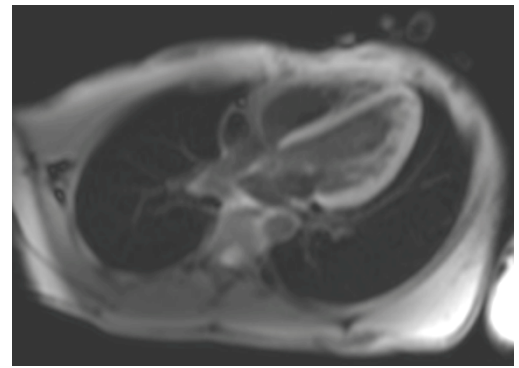
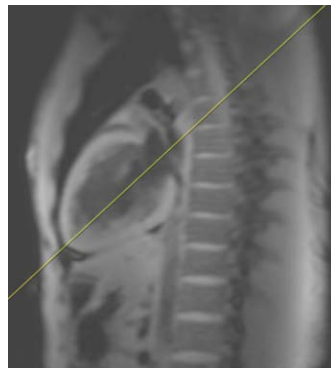


apex of the left ventricle. Perform the

6) Pseudo Horizontal Long Axis Scout

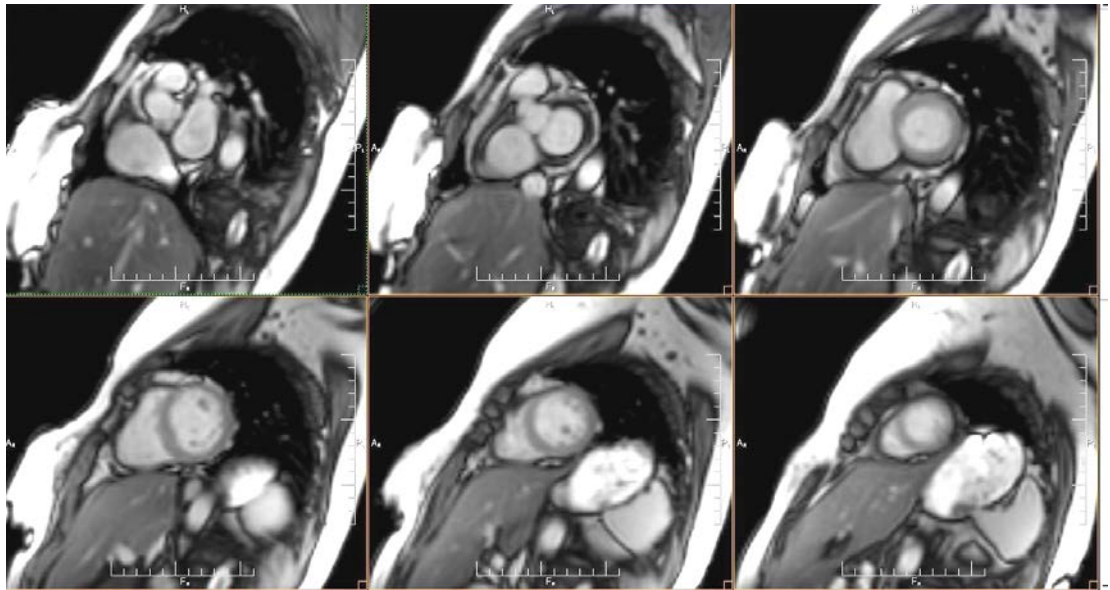
This is a dark blood, breath-hold, one slice (non-cine)

image. Prescribe using the pseudo vertical long axis scout view from the base (middle of the mitral valve) to apex of the left ventricle. Perform the localizer **at the resting lung volume**.



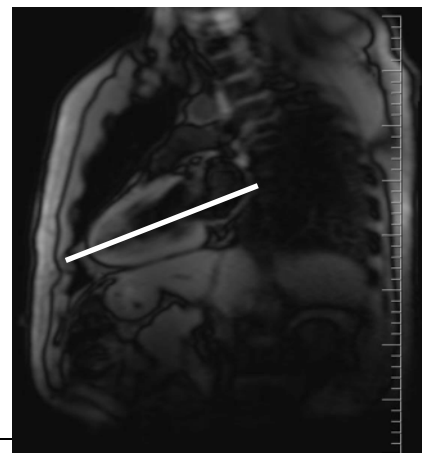
7) Short Axis Scout

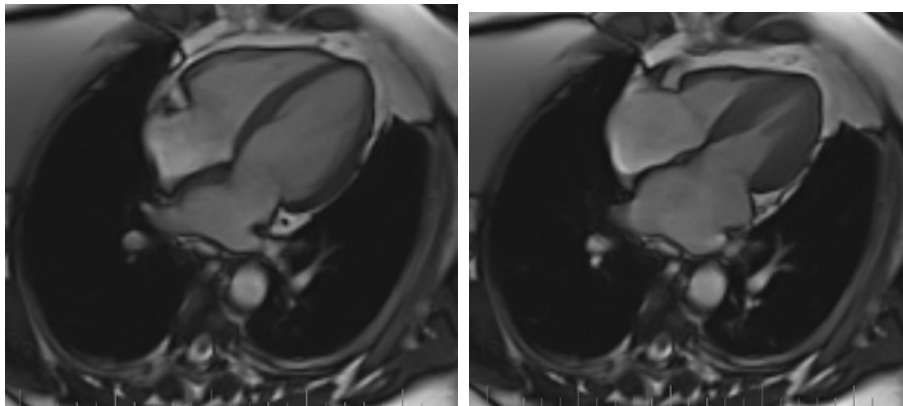
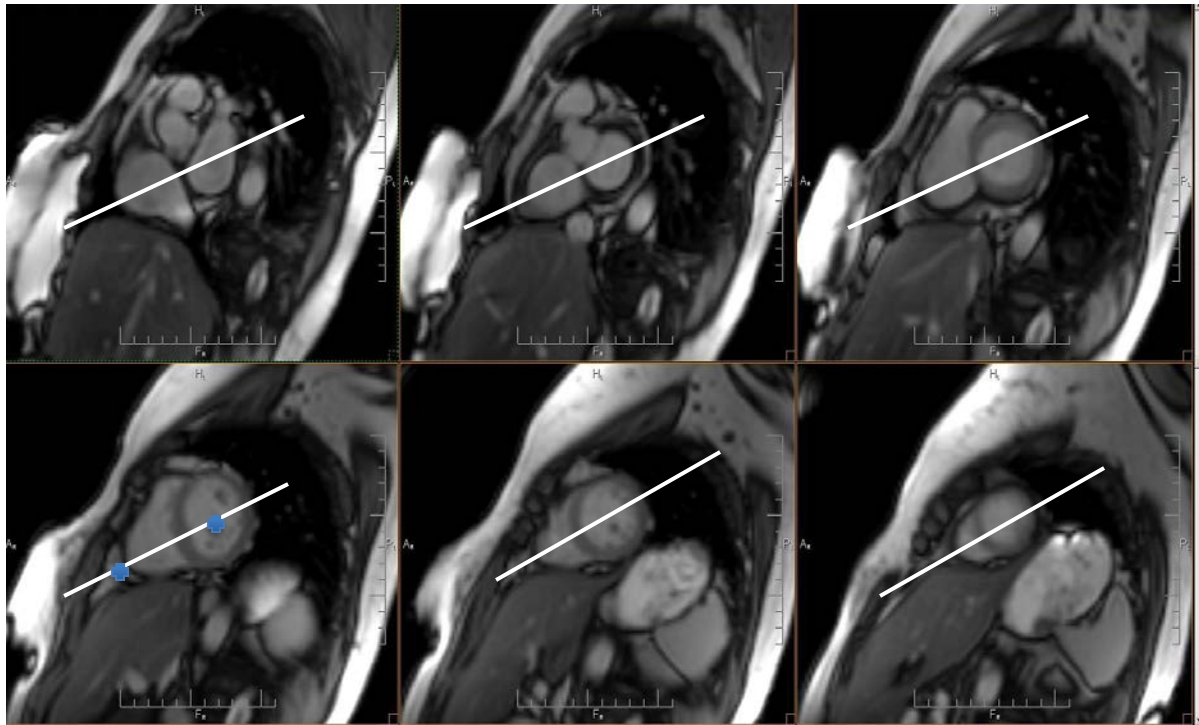
These are eight to twelve slices, bright blood/dark blood images covering the whole heart from great arteries to the apex. These images will be used for planning the four-chamber cine images and adjusting field of view.



8) Cine Four-Chamber (horizontal long axis)

This image uses SSFP, BH, with retrospective gating. Absolute temporal resolution ($TR \times \text{views per segment}$) should be between 35-45ms and reconstructed to 50 phases. This slice should be prescribed from the short axis scout images. The plane should pass through the middle of the ventricle to the apex, avoiding the aorta. The pseudo vertical long axis view will be used as a reference for checking the slice position.

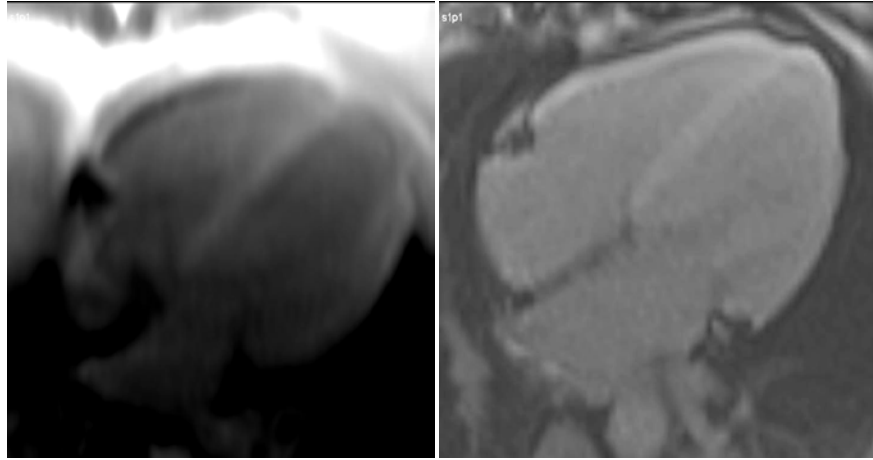




9) **T1 mapping: Pre-Contrast: four chamber view**

One horizontal long axis view (4 chamber view) is acquired, using an 11HB MOLLI protocol. The identical location is used as for the cine 4 chamber view above. Eight images are acquired in eleven heartbeats. FOV 360, base resolution should be set to 192 (interpolate to 384), flip angle 35 degree.

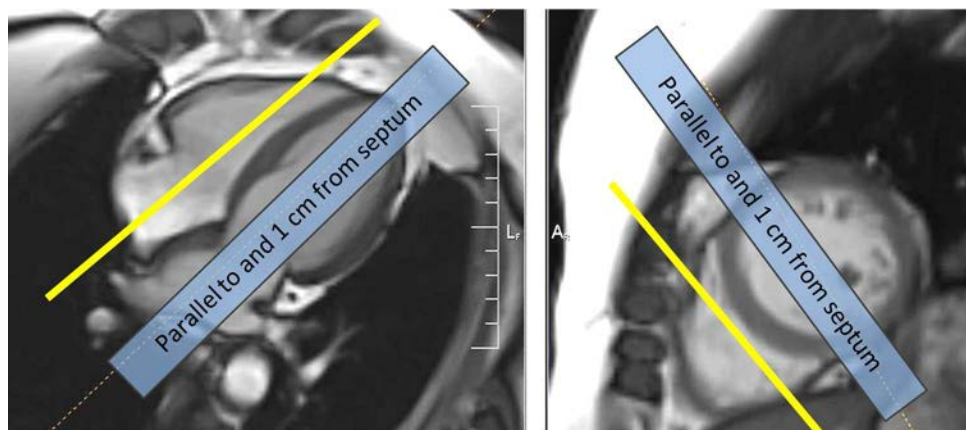
Two of the series of 8 MOLLI long axis images are shown below:



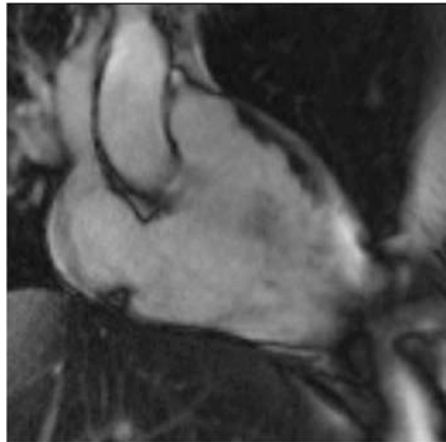
10) Cine Right Chamber Two-Chamber (vertical long axis)

This is a one-slice BH SSFP image with retrospective gating. Absolute temporal resolution ($TR \times \text{views per segment}$) between 35-45ms and reconstructed to 50 phases. The slice position should be prescribed from a four-chamber view and cross-referenced on the short axis view.

Prescription of the RV long axis cine image:



Result cine frame:



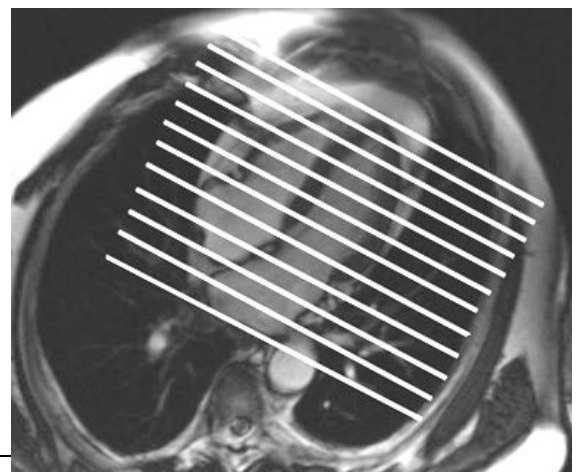
11) Gadolinium Injection – Magnevist only.

0.15 mmol/kg total dose of gadolinium-based contrast agent is infused at 1ml/sec, followed by 20 ml saline. If the I.V. gauge is small, the infusion rate could be reduced. Post contrast T1 mapping must be acquired starting at 12 and 25 minutes after gadolinium injection. Delayed enhancement images follow immediately after the 1st post contrast T1 mapping and TI scout. **Gadolinium should not be injected in participants who have impaired renal function or an allergy to contrast agent (eligibility and exclusion form).** Record the volume and time of injection on the MRI completion form.

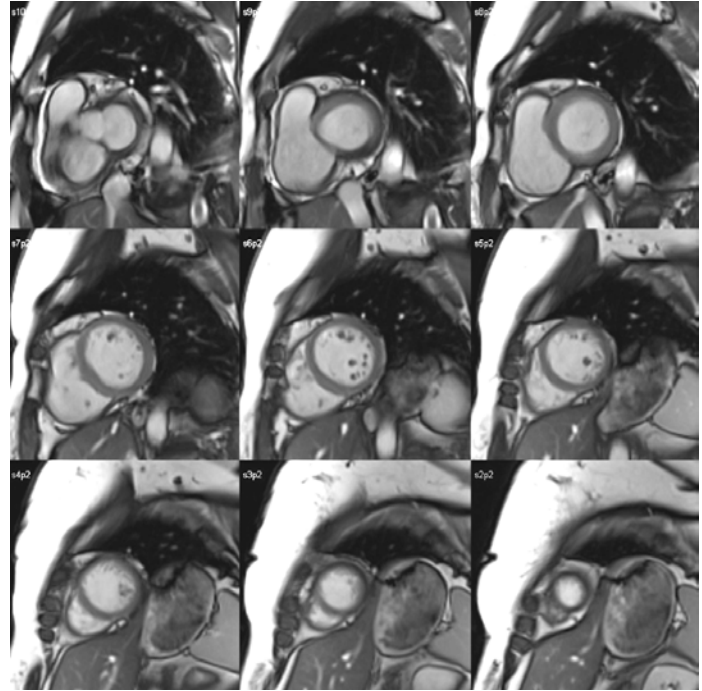
12) Cine Short Axis

Cine short axis images should be obtained while waiting for gadolinium to wash-out from the myocardium.

Breath-hold SSFP will be used to cover the whole heart from the atria to apex (minimum 12 slices). Absolute temporal resolution (TR*views per segment) between 35-



45ms and reconstructed to 50 phases. Slices should be set in descending order from base to apex. The first slice must begin 1 cm above the mitral valve plane. Flip angle should be set at the largest possible, usually around 70 degrees(1.5T), although this depends on the MRI manufacturer. For pediatric subjects, please adjust slice thickness and gap to have 10-12 slices cover the LV. For subject cannot

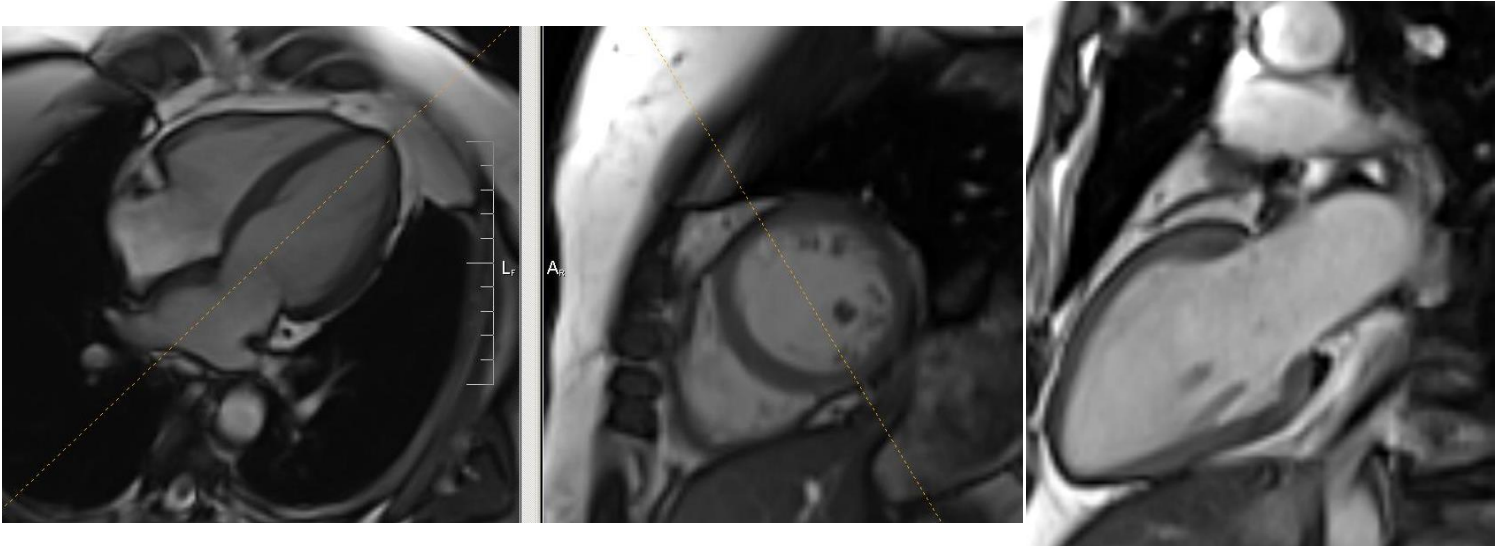


hold their breath, the SA stack can be performed with free breathing and multiple signal average.

CINE Imaging	Recommended Protocol	Vendor Specific Protocol		
		Siemens	GE	Philips
Sequence	SSFP	True FISP	FIESTA	B-FFE
TR (ms)	minimize	Min	Min	Sh
TE (ms)	minimize	Min	Min Full	Sh
Flip Angle (degrees)	maximize	Max°	70°	65°
Field of View (mm)	Depending on patient size			
Spatial Resolution (mm)	Better than 2.5*2.0*8.0			
Image Matrix	At least 128*256			
Slice Thickness (mm)	8 mm	8	8	8
Slice Gap (mm)	2 mm	2	2	2
Number of slices	Minimum of 12 short axis 1 vertical long axis 1 horizontal long axis 1 three-chamber view	Same as recommended	Same as recommended	Same as recommended
Bandwidth (Hz/pixel)	≥ 900	≥ 900	125kHz, 977 Hz/pixel	961
Parallel Imaging	Acceleration factor: 2	GRAPPA	ASSET	SENSE
Partial Fourier	No	off	No	No
Gating	Retrospective	ECG/Retro	ECG/Retrospective	Retrospective
Number of segments	≤ 20	≤ 16	12	
Temporal Resolution (ms)	30-50 msec	≤ 50	≤ 50	≤ 50
Calculated Phase	50			
Breath-hold time (s)	≤ 15	≤ 15	≤ 15	≤ 15

13) Cine Two-Chamber (vertical long axis)

This is a one-slice BH SSFP image with retrospective gating. Absolute temporal resolution ($TR \times \text{views per segment}$) between 35-45ms and reconstructed to 50 phases. The slice position should be prescribed from a four-chamber view and cross-referenced on the short axis view.

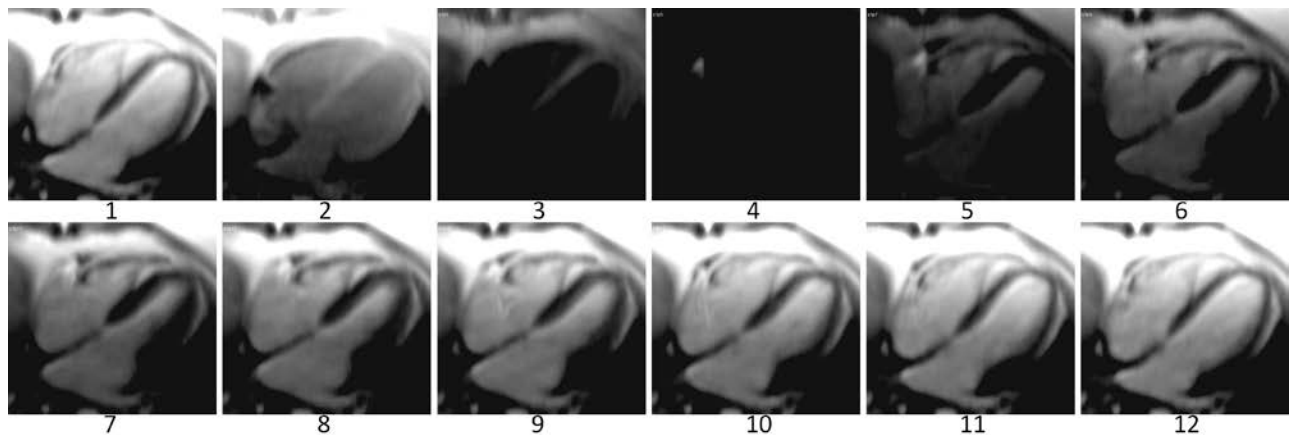


14) T1 mapping: Post-Contrast -- 4 chamber view

Acquired at 12 and 25 minutes after gadolinium injection at the same position (4 chamber view) and using the same parameters as the pre-contrast T1 mapping sequence.

15) TI Scout (Siemens), Look-locker (Philips). 4 chamber view

The purpose of these sets of images is to find the best inversion time to null the signal of myocardium. This is a bright blood (SSFP), breath hold sequence. The slice position can be copied from the mid-ventricular cine short axis slice.



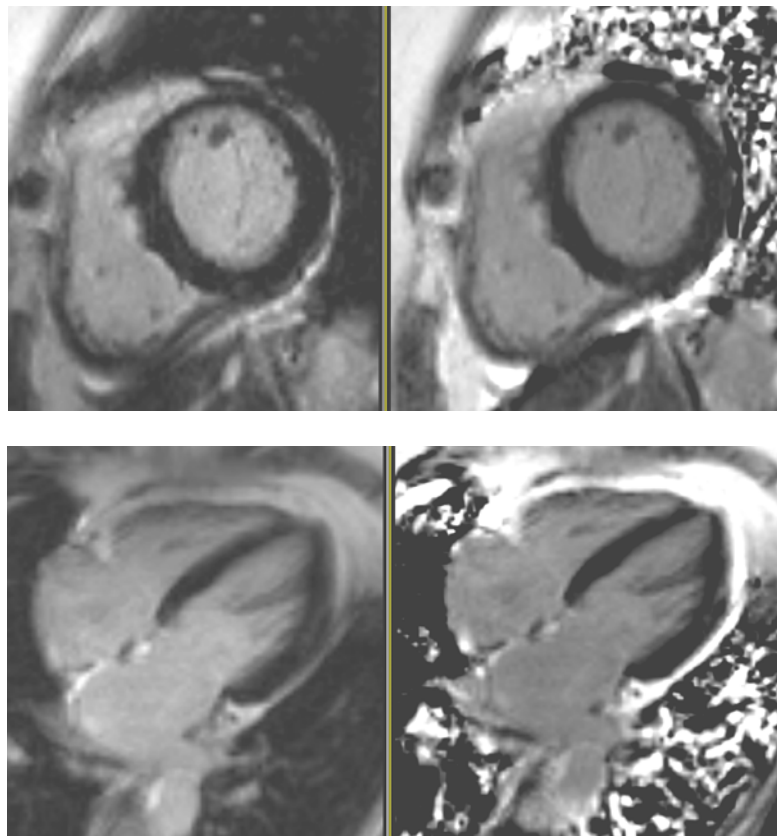
16) Short Axis SSFP Delayed Enhancement

This is single-shot PSIR SSFP on Siemens scanners. Use parallel imaging with an acceleration factor of 2. Select optimal TI and check for nulling of normal myocardium (as described above). Acquire in same short axis planes as the cine images. Use 10 mm slice thickness without gaps.

DELAYED ENHANCEMENT	Recommended Protocol	Vendor Specific Protocol	
Single-shot		Siemens	Philips
Sequence	Single-shot Inversion Recovery SSFP	True FISP IR Single-Shot	2D-bTFE SSh
TR (ms)	minimize	≤ 3.0	Shortest
TE (ms)	minimize	minimized	Shortest
Flip Angle (degrees)	maximize	65	65
Field of View (mm)	depending on patient size		
Spatial Resolution (mm)	Better than 3.0*3.0*10.0		
Image Matrix	At least 108 * 192	130 * 192	192 * 256
Slice Thickness (mm)	10	10	10
Slice Gap (mm)	none (contiguous slices)	0	0
Number of slices	Same as Cines short-axis stack	As recommended	As recommended
Magnetization Preparation	Inversion Recovery (IR)	non-sel. IR	
Inversion time (TI; ms)	Optimize, using TI scout	Start with 300 if uncertain	
Bandwidth (Hz/pixel)	≥ 900	≥ 900 Hz/pixel	1042
Parallel Imaging	Acceleration factor: 2	GRAPPA:	SENSE
Partial Fourier	None	Off	No
Trigger	every other heart beat	2 trigger pulses	every other beat
Number of segments	1	1	
Breath-hold time (s)	10-15	13 (BH optional)	2s per slice

17) **Fast Gradient Echo Delayed Enhancement Short axis**

This image uses a segmented phase sensitive inversion recovery (PSIR) spoiled gradient recalled echo (GRE) sequence. Use same geometry as the short axis cine stack; two, and four-chamber cine view. Select optimal TI and check for nulling of normal myocardium. Check for artifacts associated with arrhythmia. If necessary, increase the TI during the acquisition.



Delayed Enhancement	Recommended Protocol	Siemens	Philips	GE
Sequence	Phase Sensitive Inversion Recovery Segmented GRE	Turbo FLASH PSIR segmented	2D-bTfE SSh	Fast GRE
TR (ms)	≤ 10	≤ 10	Shortest	Min
TE (ms)	≤ 5.0	3.34	Shortest	Min Full
Flip Angle (degrees)	20-30	25	25	20
Field of View (mm)	depending on patient size			
Spatial Resolution (mm)	Better than 2.5*2.0*10.0			
Image Matrix	At least 128 * 256			
Slice Thickness (mm)	8	8	8	8
Slice Gap (mm)	2	2	2	2
Number of slices	short-axis stack, 1 four-chamber, 1 two-chamber, 1 three-chamber	As recommended	As recommended	As recommended
Magnetization Preparation	Inversion Recovery (IR)	non-sel. IR		IR
Inversion time (TI; ms)	Optimize	TI scout	Look-Locker	Cine-IR
Bandwidth (Hz/pixel)	100-150	130		31.25
Parallel Imaging		GRAPPA 2	SENSE	No
Partial Fourier	No	Off		No
Trigger	every other heart beat	2 trigger pulses	every other beat	
Number of segments	≤ 30			
Breathhold time(s)	≤ 15			

18) Fast Gradient Echo Delayed Enhancement Long axis

Use the same sequence as for short axis images. Prescribe a stack of 6 axial images covering the ventricles. The prescription is based on the Sagittal and Coronal localizer views. Use the same slice thickness and gap as the short axis delayed enhancement images. If necessary, increase the TI during the acquisition.

8. CMR Protocol Installation

The CMR core lab will email vendor specific CMR protocol to the sites. The T1 mapping sequence is not a product yet. Please contact your vendor for the T1 mapping sequence.

9. Contact Information

If you need further information about AC CMR protocol, please contact the following staff at the NIH Clinical Center

DAVID BLUEMKE, MD, PhD

Director, Radiology and Imaging Sciences

National Institutes of Health Clinical Center, Bethesda,
Maryland

Phone: 301-402-1854

Fax: 301-480-0055

Email: bluemked@nih.gov

CHIA LIU, PHD

Staff Scientist, Radiology and Imaging Sciences

National Institutes of Health Clinical Center, Bethesda,
Maryland

Phone: 301-402-5729

Fax: 301-480-1116

Email: chia-ying.liu@nih.gov

10. Update History

2012-10-12 v 1.0

2012-5-13 v 1.1 typographical errors